

11-29-2022

In-Office Needle Arthroscopic Synovial Biopsy Is an Effective Diagnostic Tool in Patients With Inflammatory Arthritis

Valerio Andreozzi

Edoardo Monaco

Cristina Garufi

Francesca Romana Spinelli

Giorgio Rossi

See next page for additional authors

Authors

Valerio Andreozzi, Edoardo Monaco, Cristina Garufi, Francesca Romana Spinelli, Giorgio Rossi, Matthew Daggett, Fabrizio Conti, and Andrea Ferretti



In-Office Needle Arthroscopic Synovial Biopsy Is an Effective Diagnostic Tool in Patients With Inflammatory Arthritis

Valerio Andreozzi, M.D., Edoardo Monaco, M.D., Cristina Garufi, M.D.,
Francesca Romana Spinelli, M.D., Giorgio Rossi, M.D., Matthew Dagget, M.D.,
Fabrizio Conti, M.D., and Andrea Ferretti, M.D.

Purpose: To assess the utility, safety, and accuracy of in-office needle arthroscopic (IONA) synovial biopsy as a diagnostic tool during treatment of drug-resistant monoarticular inflammatory arthritis of the knee. **Methods:** Consecutive patients diagnosed with rheumatoid or psoriatic arthritis with treatment-resistant monoarticular knee involvement who underwent in-office needle arthroscopic synovial biopsy were considered for inclusion. The exclusion criteria were any current malignancies or infection. All patients underwent systematic physical and laboratory examination. IONA was undertaken to inspect the macroscopic appearance of the joint, choose the biopsy site, and classify synovial inflammation. Once collected, synovial tissue specimens were examined histologically using the Krenn scoring system. **Results:** In total, 12 patients (9 male and 3 female, median age 57 [interquartile range {IQR} 8] years, median disease duration 156 [IQR 201] months) affected by psoriatic arthritis (n = 6) or rheumatoid arthritis (n = 6) were included in this study. Median operating time was 12 (IQR 11) minutes. Three biopsies per patient were collected. The success rate of specimen collection was 97%, the median postoperative 0-10 visual analog scale pain score was 2 (IQR 3), and only one minor complication occurred. **Conclusions:** Knee IONA with synovial biopsy is an effective and well-tolerated procedure that can help clinicians formulate specific treatment strategies in patients with refractory pain in the setting of rheumatoid and psoriatic arthritis. **Level of Evidence:** IV, Therapeutic case series.

Although described in the early 1990s,¹ the rate of in-office needle arthroscopy (IONA) has been increasing recently due to the improved image quality and technique.^{2,3} As the spectrum of IONA operations continues to evolve, the indications for these procedures also have expanded.^{3,4} Arthroscopy has been considered the gold standard for diagnosing intra-articular knee pathology.⁵ In the setting of intra-articular tissue biopsy, macroscopic inspection provides valuable diagnostic information while enabling the surgeon to choose exactly where to take the

synovial biopsy. The use of ultrasound (US)-guided synovial biopsy is increasing in rheumatology—for clinical research purposes more than in clinical practice—to drive the therapeutic strategy and personalize the treatment for inflammatory arthritis. Synovial tissue analysis is used as a research tool to examine disease pathogenesis, differentiate clinical phenotypes, and determine prognosis and response to therapeutic intervention.⁶

However, US-guidance biopsy has challenges associated with biopsy obtainment, mainly associated with

From the Department of Orthopaedics, Sapienza University of Rome, Rome, Italy (V.A., E.M., G.R., A.F.); Dipartimento di Scienze Cliniche Internistiche, Anestesiologiche e Cardiovascolari, Sapienza Università di Roma, Rome, Italy (C.G., F.R.S., F.C.); and Kansas City University, Kansas City, Missouri, U.S.A. (M.D.).

The authors report the following potential conflicts of interest or sources of funding: E.M. reports consultant for Arthrex, outside the submitted work. F.R.S. reports grant from Pfizer and speakers' fees from Eli Lilly, Galapagos, Amgen, and Novartis, outside the submitted work. M.D. reports consultant for Arthrex, outside the submitted work. Full ICMJE author disclosure forms are available for this article online, as [supplementary material](#).

Received April 4, 2022; accepted October 20, 2022.

Address correspondence to Cristina Garufi, viale del Policlinico 155 — 00161 Rome, Italy. E-mail: cristinagarufi@gmail.com

© 2022 THE AUTHORS. Published by Elsevier Inc. on behalf of the Arthroscopy Association of North America. This is an open access article under the CC BY-NC-ND license (<http://creativecommons.org/licenses/by-nc-nd/4.0/>). 2666-061X/22447

<https://doi.org/10.1016/j.asmr.2022.10.003>

lack of adequate intra-articular macroscopic visualization. Moreover, some authors^{7,8} have suggested that abnormal synovium at the cartilage–bone junction may have a different cellular and cytokine profile as compared with other joint sites. Arthroscopic biopsy allows the access of this area to obtain more quantitatively and qualitatively valid synovial samples.⁷ Reduced accuracy of US compared with arthroscopy in visualizing that junction may lead to in-accurate or underestimated disease in patients undergoing ultrasound guidance. Thus, arthroscopic assessment and biopsy are still considered the gold standard to collect synovial tissue specimens.^{6,9}

However, challenges exist in the assessment of inflammatory arthritis in clinical practice and in clinical research. The increased morbidity with anesthesia, risks associated with surgery, and increased costs of performing a procedure in the operating room have limited its use.⁶ The use of needle arthroscopy may address many of the traditional challenges of diagnostic arthroscopy, owing to its safe and cost-effective profile, the ability to perform the arthroscopy in the office setting, and to the resolution of needle arthroscopy that is reaching that of standard arthroscopy cameras.^{10,11}

Rheumatoid arthritis (RA) and psoriatic arthritis (PsA) are immune-mediated diseases characterized by joint involvement.^{12,13} Recent research efforts are focusing on personalized treatment based on biopsy-proven disease pathobiology and on histologic classification.¹⁴ With the present study, we evaluated whether IONA would be a safe, well-tolerated, and accurate diagnostic tool to assess knee inflammatory monoarthritis and refine the therapeutic choice in clinical practice. Therefore, we used the pathologic characteristics and the grade of inflammation of the synovial biopsy taken by IONA to modify the treatment of the rheumatologic condition. Moreover, a further aim of this study was to assess the utility, safety, and accuracy of IONA synovial biopsy as a diagnostic tool during treatment of drug-resistant monoarticular inflammatory arthritis of the knee.

Methods

Consecutive patients referred to our center from March to June 2021 with a clinical diagnosis of RA or PsA and persistently active knee monoarthritis were considered for inclusion. All patients underwent IONA of the affected knee with a maximum of 3 samples of synovial tissue taken during each procedure, with a minimum follow-up of 1 year. Inclusion criteria were age at enrollment ≥ 18 years, a diagnosis of RA or PsA, persistent knee involvement with nonresponsive to current treatment with glucocorticoids (systemic and local), nonsteroidal anti-inflammatory drugs, and disease-modifying anti-rheumatic drugs (DMARDs), as well as conventional synthetic or biological/targeted

synthetics. Exclusion criteria included concurrent malignancies or infection. Institutional review board approval (Ref: 2019-3245) and patient consent was obtained.

Clinical and Demographic Assessment

Diagnosis of RA and PsA was based on the 2010 American College of Rheumatology/European League Against Rheumatism¹⁵ and Classification Criteria for Psoriatic Arthritis,¹⁶ respectively. All patients underwent IONA of the affected knee with a maximum of 3 samples of synovial tissue taken during each procedure. The minimum follow-up time was 1 year. Patient characteristics including age, sex, ethnicity, body mass index, diagnosis, disease duration, Western Ontario and McMaster Universities Osteoarthritis Index,¹⁷ and previous treatment lines with biologic DMARDs were recorded for each patient at the time of initial assessment. Complications such as infection, deep-vein thrombosis, vasovagal reaction, nerve injury, persistent swelling, and stiffness were recorded.

Surgical Technique

All IONAs with synovial biopsy were performed by E.M. and V.A. Written informed consent was obtained from each patient before the surgical procedure. Patients did not discontinue any of the ongoing medical therapy—neither glucocorticoids nor immunosuppressants.

The disposable kit was prepared on a sterile field, including chlorhexidine scrub, a 20-cc syringe equal mixture of 1% lidocaine with epinephrine/0.25% bupivacaine, a separate 20-cc syringe with only 0.25% bupivacaine, a saline-filled 60-cc syringe, the needle arthroscopy (NanoScope; Arthrex, Naples, FL), and a 2.75-mm diameter arthroscopic grasper (Arthrex). The patient was positioned supine on the operating table with the operative lower leg free, draped in a standard sterile fashion to allow for access and manipulation of the surgical site. A stockinette was placed over the foot and ankle and secured in place distal to the tibial tuberosity with Coban wrap. The monitor from the needle arthroscope was positioned on the opposite side (Fig 1).

Mixed local anesthetic was infiltrated to each standard anteromedial (AM) and anterolateral (AL) portals and the surrounding capsule to anesthetize the area. Then, the 20-cc syringe with only 0.25% bupivacaine was injected intraarticularly. The needle arthroscope was then inserted into the knee joint through the AM portal with a posterior and lateral trajectory aimed at the intercondylar notch. After insertion of the scope, a diagnostic arthroscopy was conducted, switching the position of the arthroscope between both AM and AL portals and allowing visualization of the medial gutter, intercondylar notch, lateral gutter, and the infrapatellar

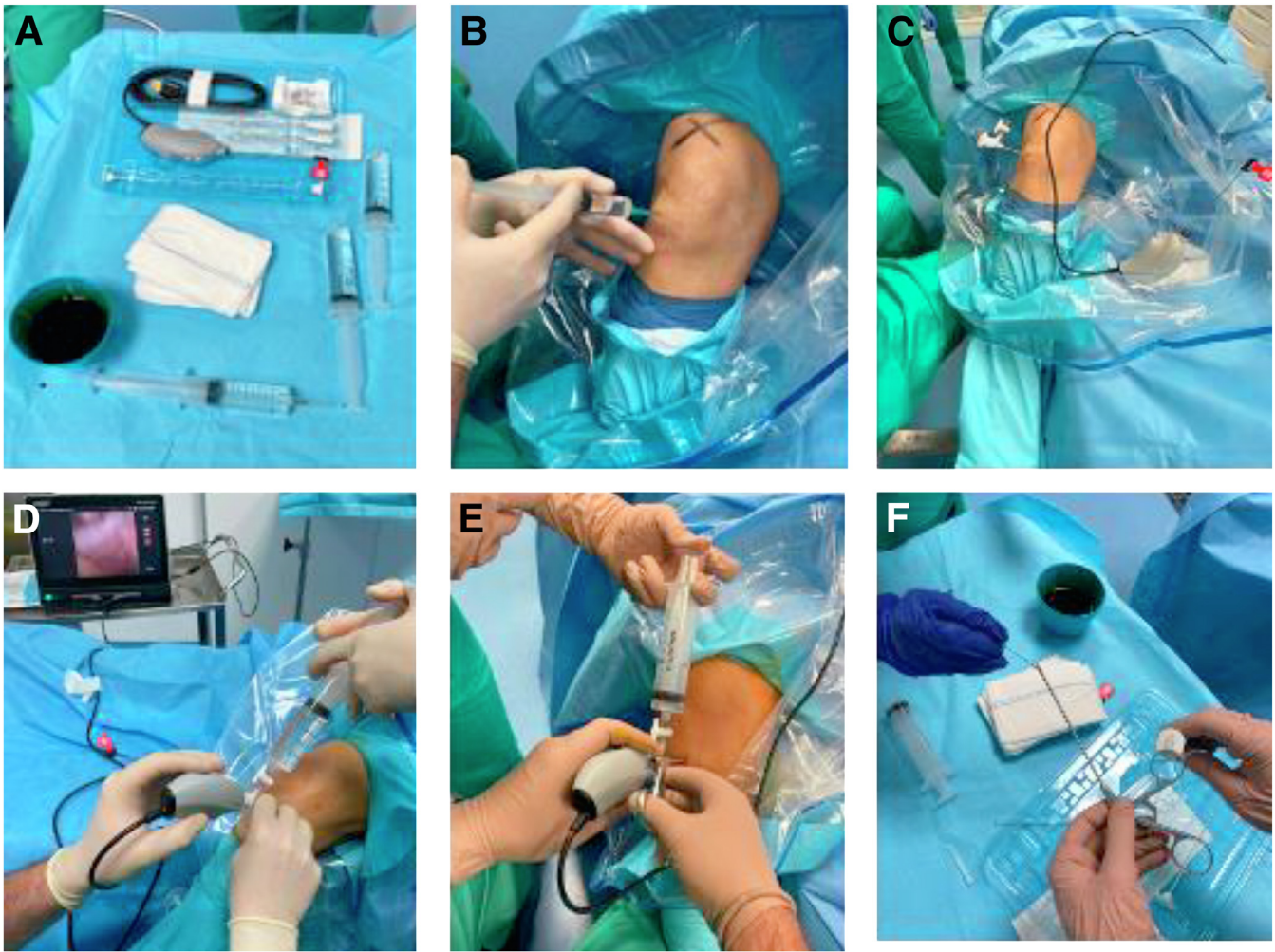


Fig 1. Diagnostic steps and approaches for in-office needle arthroscopy. (A) The needle arthroscopy set (NanoScope, Arthrex, Naples, FL) includes a zero-degree arthroscope with power cord, monitor, sharp, and blunt trochars with corresponding sheaths including inflow portals and assorted instruments. (B) A 20-mL syringe is used to infiltrate 10 mL of the mixed local anesthetic to each portal site to anesthetize the area of the right knee in a supine position. (C) The needle arthroscope is inserted into the knee joint through the primary lateral portal site with a posterior and medial trajectory aimed at the intercondylar notch of the right knee in a supine position. (D) The needle arthroscope is inserted into the knee joint and a 60-mL syringe of sterile saline, attached to the inflow port of the NanoScope, is used to distract the joint space and remove obstructing tissue blocking the arthroscope. (E) The arthroscopic grasper is inserted through the accessory medial portal under visualization of the needle scope to perform a synovial biopsy of this right knee in the supine position. (F) The synovial tissue has been removed from the grasper and is being placed into a sterile cup and submitted for pathologic evaluation.

area. A 60-mL syringe of sterile saline, attached to the inflow port of the NanoScope, was used to distract the joint space and remove obstructing tissue blocking the arthroscope. The 2.75-mm diameter grasper was used to take biopsies of the synovium using accessory working portals 1 cm medial to the standard AM portal and 1 cm lateral to the standard AL portal. Surgical confirmation of sampling site and arthroscopic grasper positioning were confirmed under visualization with the arthroscope. Moreover, macroscopic pictures were taken at the time of the biopsy for documentation. Using accessory working portals and switching the

position of the arthroscope, synovium was sampled from the intercondylar notch, medial and lateral gutters, and infrapatellar area. The synovial tissue was then removed from the grasper and placed into a sterile cup and submitted for histopathologic evaluation. Three biopsies per patient were collected.

Once the procedure was concluded, to reduce patient's postoperative discomfort, an empty 60-mL syringe was used to aspirate the saline that was injected into the joint. Band-aids were used to close the portals, and the patients were allowed to immediately mobilize the knee and walk with full weight-bearing.

Table 1. Demographic and Clinical Characteristics of the Study Population

Clinical and Demographic Characteristics	N = 12
Age, y, median (IQR)	57 (8)
Sex, male/female	9:3
BMI, median (IQR)	24.6 (6.9)
Ethnicity, n (%)	
White	11 (91.7)
Asian	1 (8.3)
RA, n (%)	6 (50)
PsA, n (%)	6 (50)
Disease duration, mo, median (IQR)	126 (120)
WOMAC at baseline, median (IQR)	38 (12)
Number of previous bDMARDs, median (IQR)	1 (1.5)

bDMARDs, biologic disease-modifying anti-rheumatic drugs; BMI, body mass index; IQR, interquartile range (IQR = Q3-Q1); PsA, psoriatic arthritis; RA, rheumatoid arthritis; WOMAC, Western Ontario and McMaster Universities Osteoarthritis Index.

At the end of the procedure, operating time, complications such as infection, deep-vein thrombosis, vasovagal reaction, nerve injury, persistent swelling and stiffness, visual analog score, a 5-point Likert scale regarding patient satisfaction, and the willingness of repeat biopsy also were recorded. We defined success rate as the rate of specimens correctly biopsied, considered appropriate for pathologic analysis.

Macroscopic and Microscopic Analysis

All patients underwent arthroscopic exploration and evaluation of knee arthritis and synovial inflammation. Macroscopic grade of synovial inflammation was assessed according to the macro-score method proposed by af Klint et al.¹⁸

For each patient, a “total synovial score,” expressed as the sum of the severity of 3 parameters (hypertrophy, vascularization, and synovitis), was recorded and classified as mild, moderate, and severe.¹⁹ Once collected with microbiopsy, synovial tissue specimens were fixed in 10% neutral-buffered formalin and examined histologically using the Krenn scoring system.²⁰ Additional sections were stored for the immunohistochemistry.

Statistical Analysis

Descriptive statistics were reported as median and IQR (interquartile range) for continuous variables and frequency and percentage for categorical variables.

Results

The present study evaluated 12 patients with RA (n = 6) or PsA (n = 6). [Table 1](#) summarizes demographic and clinical data of the patients. IONA demonstrated complete accuracy of all synovial biopsies for 35 of the 36 specimens collected, with a success rate of 97.2%. The macroscopic appearance of the synovial tissue is reported in [Figure 2](#) A-D (patients with PsA) and [Figure 2](#) E-G (patients with RA). [Figure 3](#) depicts 2 different

histologic inflammatory grades of synovial tissue specimens according to the Krenn score.

According to the pathologic analysis, 7 patients showed a synovitis score ≤ 3 , suggesting only a slight synovial inflammatory infiltration. All patients underwent a rheumatologic re-evaluation in the light of the results of the biopsy. In those patients with a low inflammatory synovial score the ongoing treatment with conventional synthetic/biologic DMARDs was not changed and local injections of glucocorticoids were performed to control the residual inflammation. In the other 5 cases, showing a median Krenn score of 6, the results of the biopsy led to a therapeutic change (3 patients started methotrexate and in 2 cases, a switch to a different biological drug was prescribed).

As per protocol, all patients showed a persistent monoarthritis of the knee despite the ongoing treatment with steroids, conventional, or biologic DMARDs. All patients were able to undergo the IONA procedure in completion. One patient reported a vasovagal reaction during IONA that was resolved after atropine administration. None of the patients reported iatrogenic chondral injuries.

None of the patients reported any issues after the arthroscopic procedure and at the 3-month follow-up examination. At the last follow-up visit (1 year of follow-up) 11 patients (91.7%) expressed their willingness to repeat to the same procedure, if clinically relevant for their condition. Clinical outcomes and synovial parameters are reported in [Table 2](#).

Discussion

Our results show that IONA of the knee and synovial tissue biopsy led to an accurate histologic assessment that directly changed the therapeutic approach in nearly one-half the study population. Moreover, synovial biopsy with IONA was a safe, accurate, quick, and well-tolerated procedure in 12 patients with refractory monoarticular knee arthritis. The patient satisfaction with the procedures was high with a significant willingness to repeat the IONA if needed.

Synovial biopsies are routinely undertaken using a variety of techniques, including standard arthroscopic biopsy, US-guided approaches, and blind needle biopsy. In a recent review, Johnsson and Najm⁶ reported similar accuracy and safety with the use of the aforementioned procedures but a greater tolerability of the US-guided technique. Furthermore, the authors reported that patients who underwent arthroscopy were less willing to accept another biopsy compared with patients undergoing US-guided needle biopsies, given that standard arthroscopic synovial biopsies are commonly performed in an operating theater and mostly performed under general anesthesia or sedation.²¹ In contrast, blind needle biopsies yield significantly less material for pathologic evaluation compared

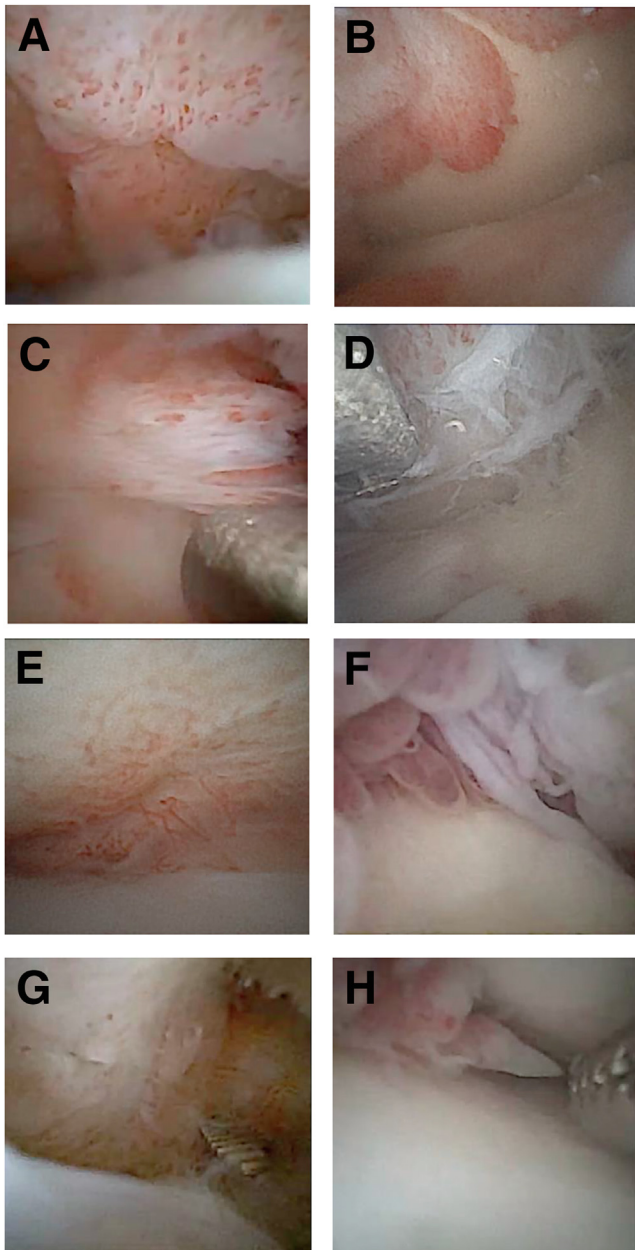


Fig 2. Examples of arthroscopic view of a patient with psoriatic arthritis (A, B, C, D) and rheumatoid arthritis (E, F, G, H). (A, B, C, D) Arthroscopic view of knees with psoriatic arthritis with the 0° NanoScope and (C-D) the synovial tissue harvesting using the arthroscopic grasper. (E, F, G, H) View of a rheumatoid arthritis knee with the 0° NanoScope from the anterolateral portal. The grasper has been placed in the medial portal with the knee in the supine position. (G-H) The grasper is harvesting synovial tissue.

with US-guided and arthroscopic procedures. In addition, US-guided and blind procedure do not allow to access to the “cartilage-pannus junction”—a critical area thought to be central in causing bone erosions—thus underestimating the extent of inflammation.^{7,8,22}

Some patients diagnosed with inflammatory diseases such as RA and PsA may experience the persistence of symptomatic monoarthritis, even when the disease is otherwise controlled. This significantly decreases patients’ treatment satisfaction and affects their quality of life.²³ After failure of intra-articular injections of glucocorticoids (in approximately 50% of patients), subsequent treatment options are unclear.²⁴ The histologic assessment of synovitis may be a source of crucial information regarding the synovial pathology and the response to treatment. In addition to the extent of inflammation, the pathologic evaluation of the synovial sample can help identify biomarkers of disease that can drive the therapeutic decision. In this light, some attempts to personalize the treatment according to the synovial phenotype recently have been performed.¹⁴ In our study, the possibility of estimating the histologic grade of inflammation supported the therapeutic decision in those difficult cases where the possible residual synovial inflammation and damage couldn’t be distinguished by physical examination or imaging alone.

In the scenario of monoarthritis resistant to systemic treatment with immunosuppressants, IONA demonstrated to be a valid tool for diagnostic purpose, to change the treatment according to the histologic grade of inflammation. The results of this study demonstrate that performing IONA is a safe and well-tolerated procedure allowing an effective biopsy in almost 100% of cases. Furthermore, more than 90% of patients was willing to repeat the procedure if necessary.

Finally, an additional potential benefit of using IONA could be to avoid articular cartilage injury. A potential advantage of using needle arthroscopic instrumentation could minimize the risk of inadvertent cartilage injury when compared with standard arthroscopy, given the smaller size of both camera and instrumentation.

No major complications following IONA were reported in the present study. Only one patient reported a vasovagal reaction. Recently, McMillan et al.²⁵ published a case series analysis on risks and complications associated with knee and shoulder IONA, showing that vasovagal events were the most common complication for all procedures. Since most of these episodes were due to needle phobia or uncomfortable sensations during the procedure, the authors suggested to turn the monitor away from the patient’s sight and to create a comfortable office environment.²⁵ In 1995, Szachnowski et al.²⁶ described 335 patients with RA undergoing in-office knee arthroscopy with major and minor complication rates of 1.2% and 12.8%, respectively. Afterwards, Baeten et al.²⁷ reported minor complications in less than 10% and no major complications after IONA for knee synovitis. These studies suggested that office-based small-bore arthroscopes are safe and effective means to obtain direct visualization of the joint.

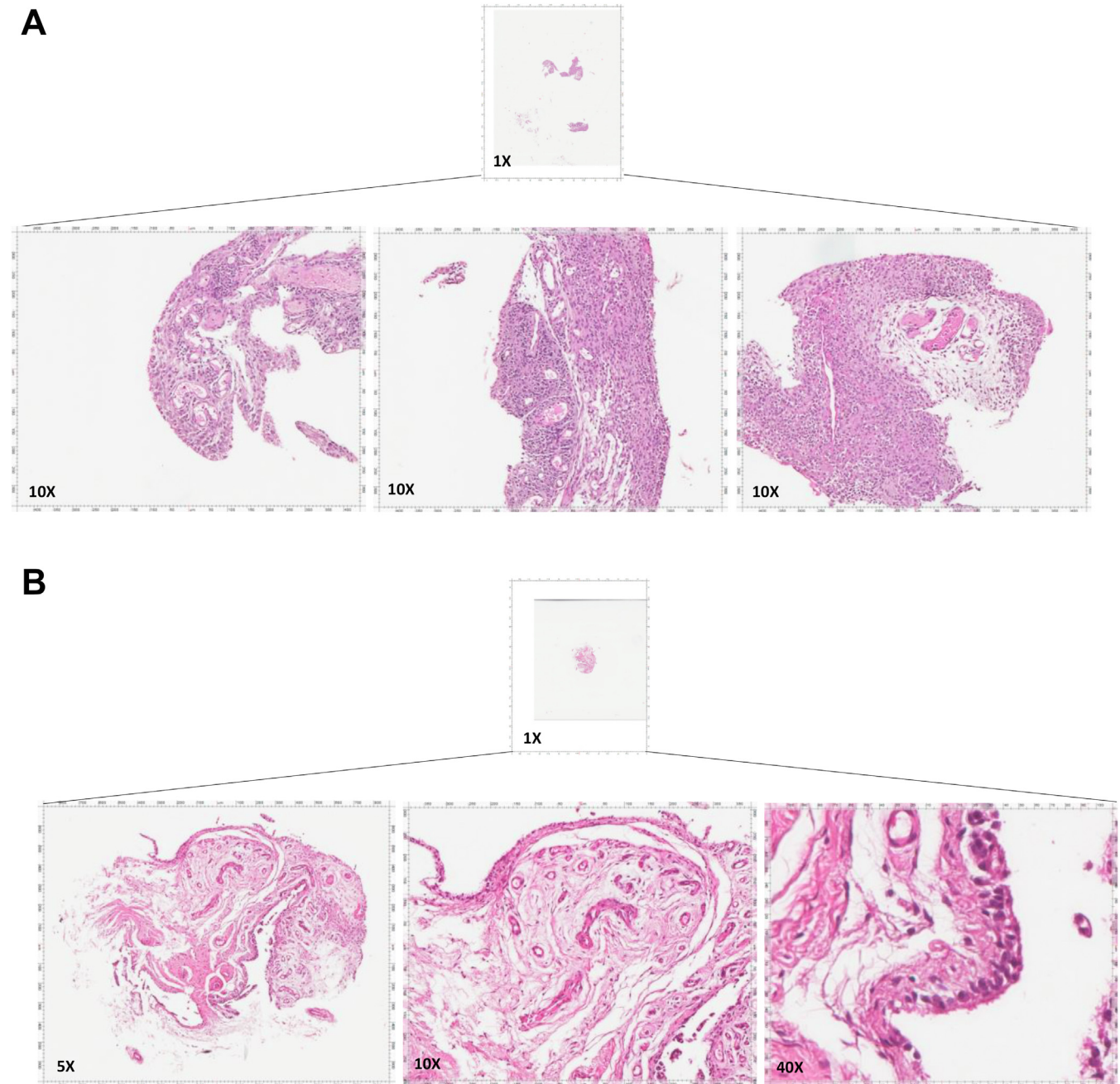


Fig 3. Histologic findings showing the synovium architecture of the biopsies taken with the grasper. Depicted are 2 examples of the histomorphologic feature of 2 synovial specimens stained with hematoxylin and eosin for the evaluation of inflammatory infiltrate. (A) Original magnification 10× of a specimen showing high-grade synovitis (Krenn synovitis score = 6) in a patient with rheumatoid arthritis. (B) Original magnification 5×, 10×, 40× showing low-grade synovitis (Krenn synovitis score = 2) in a patient with psoriatic arthritis.

New generation of IONA allows to take arthroscopy even further than before. With increased safety and tolerability as well as decreased costs compared with traditional arthroscopy, IONA can be a successful tool for synovial analysis. Our findings suggest that the integration of the synovial tissue analysis into standard of care treatment for inflammatory arthritis will help pursue individualized, precise treatment strategies.

More research is required in examining the role of IONA in conjunction with advanced synovial tissue analysis to guide the rational matching of patients with targeted antirheumatic drugs.

Limitations

This study is not without limitations. The small size of the cohort is due to the specific patient population

Table 2. Surgical and Synovial Characteristics of the Study Population

Clinical Outcomes and Synovial Parameters	N = 12
Operating time, min, median (IQR)	12 (11)
Success rate, %	97.2
Iatrogenic chondral injuries, n (%)	0 (0)
Minor complications, n (%)	1 (8)
Postoperative pain, (0-10 cm VAS), median (IQR)	2 (3)
Likert scale, (1-5), median (IQR)	4.4 (1)
Willingness of repeat biopsy, yes, n (%)	11 (91.7)
Macroscopic synovitis, n (%)	
Low	3 (25)
Moderate	5 (41.7)
Severe	4 (33.3)
Krenn score, median (IQR)	2 (4)

NOTE. Success rate indicates the rate of specimens considered appropriate for pathologic analysis; minor complications indicate vasovagal reaction.

IQR, interquartile range (IQR = Q3-Q1); VAS, visual analog score.

included in the study, restricted to those patients presenting with persistent inflammatory knee monoarthritis despite the ongoing treatment with DMARDs. A further limitation is the lack of a longer clinical follow-up to confirm the effectiveness of IONA-driven therapeutic change. Finally, the restriction to patients with RA and PsA may not reliably extrapolate to other inflammatory rheumatologic conditions.

Conclusions

Knee IONA with synovial biopsy is an effective and well-tolerated procedure that may help clinicians formulate specific treatment strategies in patients with refractory pain in the setting of RA and PsA.

References

- Halbrecht JL, Jackson DW. Office arthroscopy: A diagnostic alternative. *Arthroscopy* 1992;8:320-326.
- Patel KA, Hartigan DE, Makovicka JL, Dulle DL 3rd, Chhabra A. Diagnostic evaluation of the knee in the office setting using small-bore needle arthroscopy. *Arthrosc Tech* 2018;7:e17-e21.
- Zhang K, Crum RJ, Samuelsson K, Cadet E, Ayeni OR, de Sa D. In-office needle arthroscopy: A systematic review of indications and clinical utility. *Arthroscopy* 2019;35:2709-2721.
- Stornebrink T, Emanuel KS, Shimozone Y, Karlsson J, Kennedy JG, Kerkhoffs G. A change in scope: Redefining minimally invasive. *Knee Surg Sports Traumatol Arthrosc* 2020;28:3064-3065.
- Treuting R. Minimally invasive orthopedic surgery: Arthroscopy. *Ochsner J* 2000;2:158-163.
- Johnsson H, Najm A. Synovial biopsies in clinical practice and research: Current developments and perspectives. *Clin Rheumatol* 2021;40:2593-2600.
- Wechalekar MD, Smith MD. Utility of arthroscopic guided synovial biopsy in understanding synovial tissue pathology in health and disease states. *World J Orthop* 2014;5:566-573.
- Vordenbaumen S, Joosten LA, Friemann J, Schneider M, Ostendorf B. Utility of synovial biopsy. *Arthritis Res Ther* 2009;11:256.
- Najm A, Orr C, Heymann MF, Bart G, Veale DJ, Le Goff B. Success rate and utility of ultrasound-guided synovial biopsies in clinical practice. *J Rheumatol* 2016;43:2113-2119.
- Daggett MC, Busch K, Ferretti A, Monaco E, Bruni G, Saithna A. Percutaneous anterior cruciate ligament repair with needle arthroscopy and biological augmentation. *Arthrosc Tech* 2021;10:e289-e295.
- Lavender C, Lycans D, Kopiec A, Sayan A. Nanoscopic single-incision anterior labrum repair. *Arthrosc Tech* 2020;9:e297-e301.
- Smolen JS, Aletaha D, McInnes IB. Rheumatoid arthritis. *Lancet* 2016;388:2023-2038.
- Menter A. Psoriasis and psoriatic arthritis overview. *Am J Manag Care* 2016;22:s216-s224 (suppl 8).
- Humby F, Durez P, Buch MH, et al. Rituximab versus tocilizumab in anti-TNF inadequate responder patients with rheumatoid arthritis (R4RA): 16-week outcomes of a stratified, biopsy-driven, multicentre, open-label, phase 4 randomised controlled trial. *Lancet* 2021;397:305-317.
- Radner H, Neogi T, Smolen JS, Aletaha D. Performance of the 2010 ACR/EULAR classification criteria for rheumatoid arthritis: A systematic literature review. *Ann Rheum Dis* 2014;73:114-123.
- Taylor W, Gladman D, Helliwell P, et al. Classification criteria for psoriatic arthritis: Development of new criteria from a large international study. *Arthritis Rheum* 2006;54:2665-2673.
- Wolfe F, Kong SX. Rasch analysis of the Western Ontario MacMaster questionnaire (WOMAC) in 2205 patients with osteoarthritis, rheumatoid arthritis, and fibromyalgia. *Ann Rheum Dis* 1999;58:563-568.
- af Klint E, Catrina AI, Matt P, et al. Evaluation of arthroscopy and macroscopic scoring. *Arthritis Res Ther* 2009;11:R81.
- Trisolino G, Favero M, Lazzaro A, et al. Is arthroscopic videotape a reliable tool for describing early joint tissue pathology of the knee? *Knee* 2017;24:1374-1382.
- Krenn V, Morawietz L, Burmester GR, et al. Synovitis score: Discrimination between chronic low-grade and high-grade synovitis. *Histopathology* 2006;49:358-364.
- Kane D, Veale DJ, FitzGerald O, Reece R. Survey of arthroscopy performed by rheumatologists. *Rheumatology (Oxford)* 2002;41:210-215.
- van de Sande MG, Gerlag DM, Lodde BM, et al. Evaluating antirheumatic treatments using synovial biopsy: A recommendation for standardisation to be used in clinical trials. *Ann Rheum Dis* 2011;70:423-427.
- Fisher BA, Keat A. Should we be using intraarticular tumor necrosis factor blockade in inflammatory monoarthritis? *J Rheumatol* 2006;33:1934-1935.
- Sullivan MM, Pham MM, Marks LA, Aslam F. Intra-articular therapy with methotrexate or tumor necrosis

- factor inhibitors in rheumatoid arthritis: A systematic review. *BMC Musculoskelet Disord* 2021;22:792.
25. McMillan S, Chhabra A, Hassebrock JD, Ford E, Amin NH. Risks and complications associated with intra-articular arthroscopy of the knee and shoulder in an office setting. *Orthop J Sports Med* 2019;7: 2325967119869846.
 26. Szachnowski P, Wei N, Arnold WJ, Cohen LM. Complications of office based arthroscopy of the knee. *J Rheumatol* 1995;22:1722-1725.
 27. Baeten D, Van den Bosch F, Elewaut D, Stuer A, Veys EM, De Keyser F. Needle arthroscopy of the knee with synovial biopsy sampling: Technical experience in 150 patients. *Clin Rheumatol* 1999;18:434-441.