

8-2012

Psoas Syndrome: A Frequently Missed Diagnosis

Andrea Tufo

Gautam Desai

W. Joshua Cox

Psoas Syndrome: A Frequently Missed Diagnosis

Andrea Tufo, OMS IV
 Gautam J. Desai, DO
 W. Joshua Cox, DO

Psoas syndrome is an easily missed diagnosis. However, it is important to consider this condition as part of the differential diagnosis for patients presenting with low back pain—particularly for osteopathic physicians, because patients may view these practitioners as experts in musculoskeletal conditions. The authors describe the case of a 48-year-old man with a 6-month history of low back pain that had been attributed to “weak core muscles.” The diagnosis of psoas syndrome was initially overlooked in this patient. After the correct diagnosis was made, he was treated by an osteopathic physician using osteopathic manipulative treatment, in conjunction with at-home stretches between office treatments. At his 1-month follow-up appointment, he demonstrated continued improvement of symptoms and a desire for further osteopathic manipulative treatment.

J Am Osteopath Assoc. 2012;112(8):522-528

Psoas syndrome may manifest as any of a variety of clinical scenarios involving low back pain and often poses a diagnostic challenge. However, many patients have certain symptoms in common, including pain in the lumbosacral region when sitting or standing, delay or difficulty in achieving a fully erect posture, pain in the contralateral gluteal region, and radiation of pain down the opposite leg (generally stopping proximal to the knee).¹ Symptoms may mimic those of a herniated nucleus pulposus.¹ In the differential diagnosis, other musculoskeletal and visceral causes of pain, such as colon cancer, colon diverticulitis, femoral bursitis, hip arthritis, prostatitis, salpingitis, and ureteral calculi, must be ruled out as the source of low back pain.²

It is important to remember the existence of fascial connections when treating patients with psoas syndrome. Fascia envelops the psoas muscle as well as the adjacent viscera, and it connects to the internal crus of the diaphragm.³ The ureter lies just medial to the psoas muscle. Thus, passage of a kidney stone through the ureter may cause irritation of the psoas muscle. Dysfunction of the psoas muscle can cause restriction of the diaphragm, and, conversely, a restricted diaphragm has potential to cause psoas muscle dysfunction.³

Other anatomic considerations include the parietal peritoneum, which covers the psoas muscle as well as the appendix. Therefore, an inflamed appendix can cause signs of irritation of the psoas muscle.⁴ It has been postulated that persistent spasm of the psoas muscle is responsible for more disability than pathologic conditions of other back muscles.¹

In the present article, we describe the case of a 48-year-old man with a history of low back pain in whom the diagnosis of psoas syndrome was initially overlooked. After the correct diagnosis was made, osteopathic manipulative treatment (OMT) was used to treat the patient, in conjunction with at-home stretches.

Report of Case

A 48-year-old white man presented with a 6-month history of low back pain. He recalled the morning when he first noticed pain in his lumbar region; he awoke to find himself “hunched over” with marked difficulty standing up straight. The pain, which shifted back and forth from his

From the Kansas City University of Medicine and Biosciences’ College of Osteopathic Medicine in Missouri.

Financial Disclosures: None reported.

Address correspondence to Gautam J. Desai, DO, FACOPF, Assistant Professor, Department of Family Medicine, Kansas City University of Medicine and Biosciences’ College of Osteopathic Medicine, 1750 Independence Ave, SEP 354, Kansas City, MO 64106-1453.

E-mail: gdesai@kcumb.edu

Submitted August 29, 2011; revision received March 7, 2012; accepted March 28, 2012.

Consider Psoas Syndrome if Patient Presents With:

L1 or L2 vertebra rotated left, sidebent right (key dysfunction)

L3-L5 vertebrae rotated right, sidebent left

Body flexed at waist and sidebent left

Right pelvic shift

Left foot everted

Left psoas spasm (with restricted hip extension)

Sacrum rotated on left oblique axis

Right piriformis spasm or tender point

Pain radiating down right leg

Positive result of Thomas test on the left side

Patient states that he or she was able to quickly assume extended position after being in flexed position for some time (eg, quickly standing upright after gardening)

Figure 1. Osteopathic structural examination findings that are suggestive of left psoas syndrome. The key dysfunction in this syndrome is considered to be lumbar vertebrae L1 or L2 rotated left and sidebent right. In addition to these findings, the osteopathic physician must also take into account the patient's history and physical examination results to make a diagnosis.

right to left lumbosacral region, was described as aching, episodic, and fluctuating in intensity. He also had occasional bouts of pain and numbness that radiated into his buttocks and down to his knees, with the right lower extremity being more frequently affected. His back felt stiff and he had an especially hard time achieving a fully erect posture after prolonged sitting. He found a position of ease by lying flat on his back with his hips flexed, knees extended, and legs resting against a wall. He believed that this position stretched the tight muscles in his legs.

The patient denied a history of trauma or increased pain with coughing or sneezing. He also denied any bowel or bladder dysfunction. He had been seeing a chiropractor regularly and performing stretches and "core-strengthening exercises" at home, but this therapy gave him little relief. In addition, he had been prescribed cyclobenzaprine hydrochloride, but he did not like the groggy feeling caused by the drug, so he discontinued its use.

The patient's medical, social, and family histories were noncontributory. Physical examination revealed a well-nourished individual with no signs of acute distress. His vital signs included a blood pressure of 122/78 mm Hg, a body temperature of 98.0°F (36.7°C), a pulse of 80 beats per minute, and a respiratory rate of 16 breaths per minute. He had normal muscle strength (5/5) in his lower extremities bilaterally. His patellar and Achilles deep tendon

reflexes were +2/4 bilaterally. He had decreases in normal passive ranges of motion as follows: hip flexion reduced by approximately 40% bilaterally, left hip internal rotation reduced by approximately 75%, left hip external rotation reduced by approximately 60%, left hip extension reduced by approximately 60%, and right hip extension reduced by approximately 35%.

An osteopathic structural examination revealed, in addition to the previously mentioned findings, an anterior rotation of the right innominate bone; a left-on-right backward sacral torsion; lumbar vertebrae L1-L2 flexed, rotated left, and sidebent left; and L3-L5 neutral, rotated right, and sidebent left. *Figure 1* lists diagnostic findings gathered during an osteopathic structural examination that may be suggestive of psoas syndrome.

Treatment

The patient was treated by an osteopathic physician using the OMT technique of muscle energy for his lumbar dysfunction, innominate rotation, and sacral torsion. Muscle energy was also used to address the patient's restricted range of motion in hip extension, internal rotation, and external rotation. Articulatory techniques were used to release sacroiliac joint restriction affecting the sacrum and innominate region. Integrated neuromuscular release and myofascial release were directed at the patient's hypertonic muscles around his lumbar spine. Finally, a high-velocity, low-amplitude technique was used to correct the somatic dysfunction in his lumbar spine. The patient underwent about 3 sessions of these treatments over a period of 4 weeks.

The patient was instructed to perform exercises at home between his OMT sessions, including lunge stretches to stretch his iliopsoas muscle (*Figure 2*) and external rotations of the hip to stretch his piriformis muscle (*Figure 3*). The lunge stretches involved the patient stepping forward with 1 foot while the opposite foot remained flat on the ground. He was instructed to keep his torso erect and to not bend over the front leg. He was told to then lean forward until he could feel the stretch in his back leg. To stretch his piriformis muscle, he was instructed to place the lateral aspect of his leg on the edge of a bed with the knee bent. He was to then drop his hips down and lean forward over the bed until a stretch was felt in the leg. The patient was asked to repeat both stretches 10 times bilaterally, twice a day, and to hold each stretch for 30 seconds.

Follow-Up

At 1-month follow-up, improvement was noted in both the subjective report by the patient and the objective physical and osteopathic structural examination findings. The patient stated that after an initial, brief flare of symptoms

CASE REPORT



Figure 2. Modified version of the lunge stretch exercise that was assigned to the patient with psoas syndrome as a home stretch exercise. The lunge stretch involved the patient stepping forward with 1 foot while the opposite foot remained flat on the ground. Keeping the torso erect and not bending over the front leg, the patient leaned forward until he could feel the stretch in the iliopsoas muscle in his back leg. Home exercises were used as treatment in addition to office sessions of osteopathic manipulative treatment.

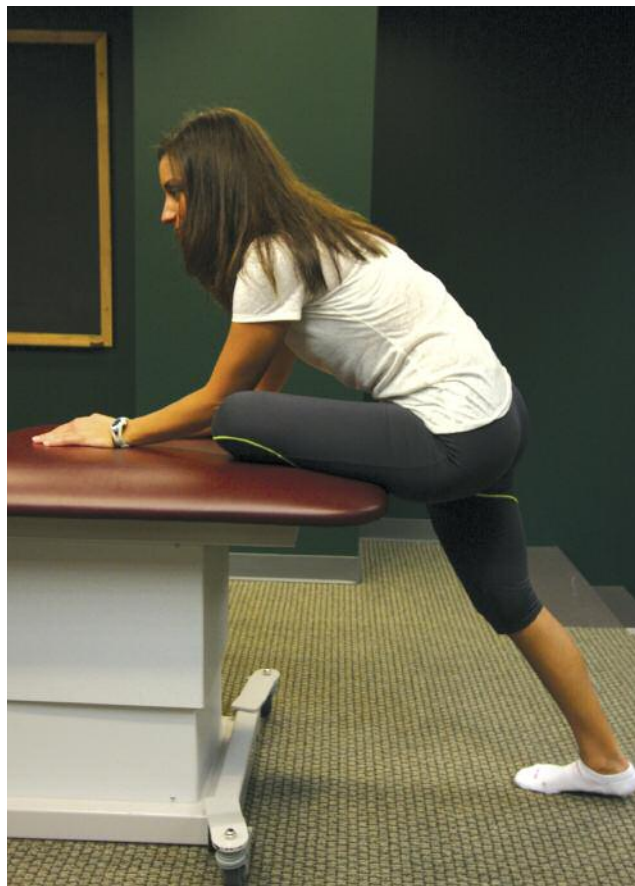

Figure 3. The type of at-home exercise used by the patient with psoas syndrome for external rotations of the hip to stretch his piriformis muscle. He placed the lateral aspect of his leg on the edge of a bed with the knee bent. He then dropped his hips down and leaned forward over the bed until a stretch was felt in the leg's piriformis muscle. Home exercises were used as treatment in addition to office sessions of osteopathic manipulative treatment.

on the first day of receiving OMT, he had a few virtually pain-free days. He added that there was ultimately a resolution of the pain and paresthesias down his legs, followed by gradual recurrence but not to the level of the initial presentation.

The patient reported faithfully performing his assigned stretches, in addition to the core-strengthening exercises recommended by his previous, chiropractic provider. The core-strengthening exercises involved the patient doing sit-ups on an exercise ball, as well as lying on his back with his hips and knees bent to 90° and rotating his legs from side to side.

Physical examination revealed that the patient had increased range of motion, with his left hip internal rotation reduced to 50% and his right hip internal rotation reduced

to 35%. His external hip rotation was no longer restricted on either side. Right hip flexion was reduced to 30%, and left hip flexion was reduced to 15%, which were both marked improvements from his initial visit. Osteopathic manipulative treatment was repeated with the same protocol as the previous visit, and the patient continued to improve.

Comment

The psoas major muscle attaches to the T12-L4 vertebral bodies and the L1-L5 transverse processes at its origin. Its primary role is to flex the hip, but it also plays a role in sidebending the spine.⁵ In individuals who have a psoas minor muscle, this muscle usually attaches to the T12-L1 vertebral bodies at its origin and inserts at the iliac fascia

bilaterally. The psoas minor muscle assists the psoas major muscle in flexion of the hip and lumbar spine.⁵ The psoas major muscle joins with the iliacus muscle (forming the iliopsoas), which continues over the superior ramus of the pubic bone to have its final insertion on the lesser trochanter.²

In most people, the iliopsoas muscle is slightly hyper-tonic. In athletes, such as runners, who frequently use the psoas major muscle, a hyperlordosis may be observed.^{6(p473)} It is postulated that psoas syndrome may frequently begin as a bilateral muscle spasm, which eventually becomes more prominent on 1 side.¹ The mechanism of injury can be acute (eg, the muscle is held in a shorted position for an extended period and then rapidly stretched) or chronic (eg, numerous repetitions of sit-ups with legs extended).²

It has also been reported in the literature that leg-length discrepancies, including those arising from the improper use of a heel lift, might irritate the psoas muscle, leading to psoas syndrome.⁷

The Thomas test can be used to help identify patients with psoas muscle spasm. In this test, patients lie supine with their legs hanging off the end of a table.^{6(p479-480)} They are instructed to flex their hips and knees, hugging their knees to the chest. The patient then slowly extends 1 leg. The osteopathic physician may place his or her hand under the lumbar spine during the test to monitor the tissue for increased lordosis. A positive test result is indicated by increased lumbar lordosis or by the patient's inability to allow the leg to drop to the table when the hip and knee are extended (Figure 4A).^{6(p479-480)} In a negative test result, the patient can fully extend 1 leg while the other is flexed (Figure 4B).^{6(p479-480)}

Psoas syndrome may be confused with snapping hip syndrome, with which there is some overlap of symptoms. In snapping hip syndrome, an audible "snap" can be heard. This sound is created—in cases of internal snapping hip syndrome—by the iliopsoas tendon "snapping" over the iliopectineal eminence of the pelvis, the lesser trochanter, or the anterior inferior iliac spine.⁸ (In external snapping hip syndrome, there is a snapping of the iliotibial band or gluteus maximus over the greater trochanter.) A recent study⁹ found that the most common cause of snapping hip syndrome is the iliopsoas tendon slipping over the iliac muscle, which occurs most frequently when the hip is moved

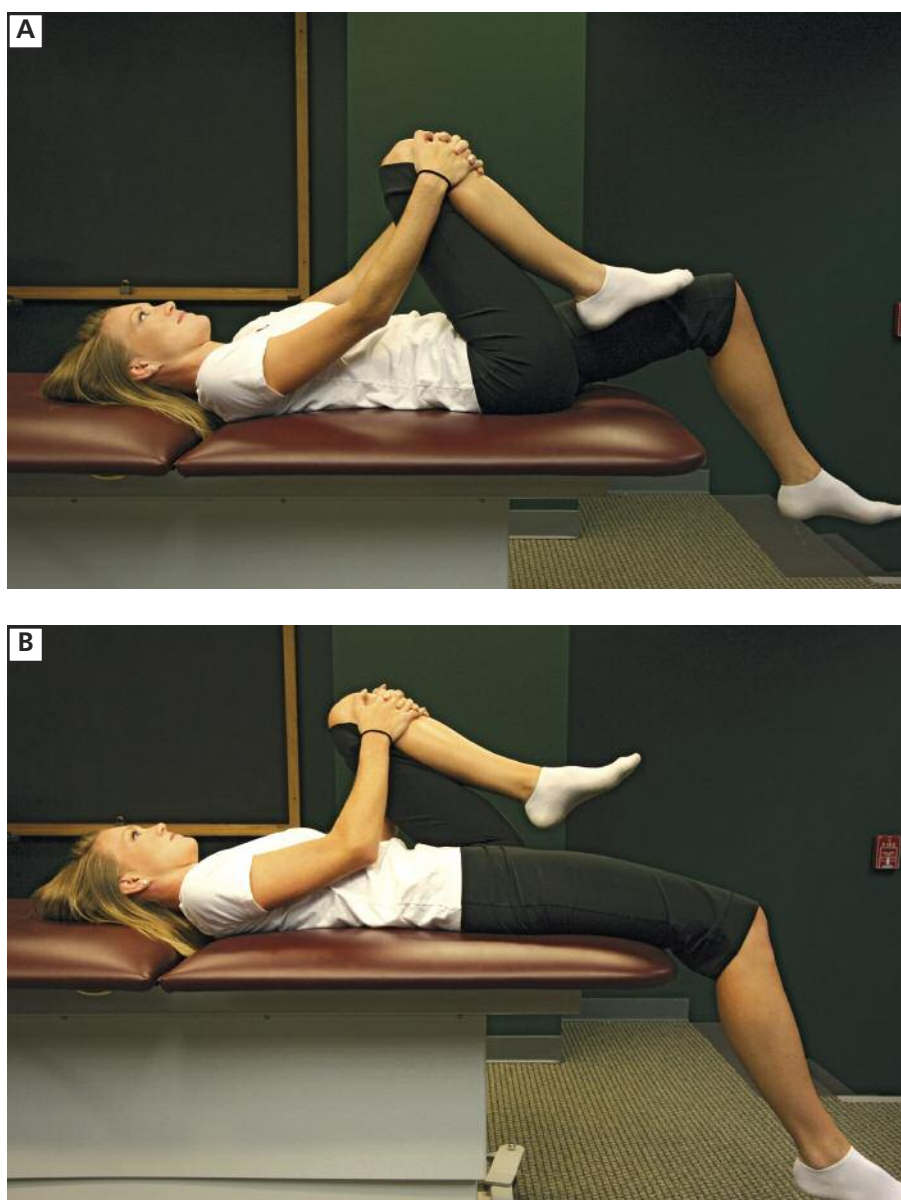


Figure 4. For a patient with psoas muscle spasm, a positive result on the Thomas test is indicated by increased lumbar lordosis or by (A) the supine patient's inability to allow his or her leg to drop to the table when the hip and knee are extended. In a negative test result, (B) the supine patient can fully extend the leg to the table while the other leg is flexed.

CASE REPORT

from flexion, abduction, and external rotation into extension. Typically, the snap is painless, but occasionally pain will be felt in the anterior hip.⁸ Although a snap may be associated with psoas syndrome, the treatment approaches to a snapping iliopsoas tendon and psoas syndrome are slightly different.⁸

After visceral causes of psoas syndrome have been ruled out by means of patient history and physical examination, the osteopathic physician can focus on treatment, keeping the fascia in mind. In addition to treatment directed at the psoas muscle, OMT techniques should also be directed at regions of fascial attachments. For example, because the fascia overlying the psoas muscle extends superiorly to connect with portions of the diaphragm, treatments directed at this region may help achieve the goal of relieving spasm of the psoas muscle.³ Doming of the diaphragm may be useful after the initial spasm has somewhat subsided. In this technique, the patient lies in the supine position, and the osteopathic physician places his or her thumbs just inferior to the anterior costal margin bilaterally, applying a firm posterior and cephalad pressure.¹⁰ This pressure is maintained during inhalation and gently increased during exhalation. This technique is repeated after respiratory cycles until treatment goals are achieved.¹⁰

If a patient with a psoas muscle spasm is left untreated, the body attempts to compensate for the change in structure, potentially causing several additional somatic dysfunctions that lead to additional symptoms.¹ Many of these compensatory patterns were observed in our patient, who had left psoas syndrome. The patient presented with the key dysfunction of L1-L2 vertebrae rotated left (toward the side of dysfunction), representing the characteristics of Fryette's Type II spinal mechanics. The rest of the patient's lumbar spine had the characteristics of Fryette's Type I spinal mechanics, rotating in the opposite direction, with L3-L5 vertebrae rotated right. With the lumbar spine sidebent to the left, the pelvis shifts to the right, creating an additional strain on the right

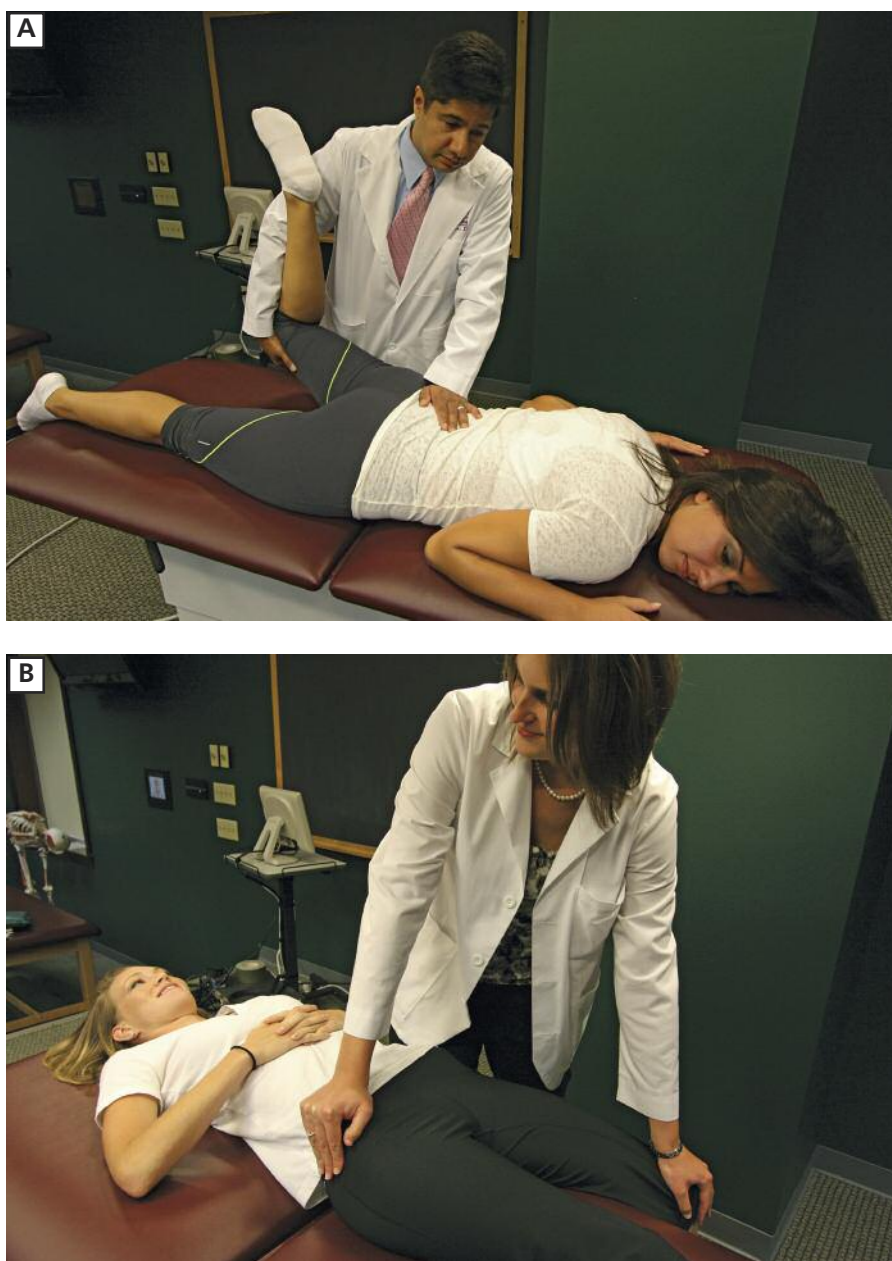


Figure 5. The application of muscle energy technique to (A) a patient lying prone, with the osteopathic physician standing at the side of the table. The osteopathic physician lifts the leg on the involved side, extending the hip, while the osteopathic physician's other hand applies pressure to the pelvis from the opposite (ie, posterior) side, to block linkage during treatment. The patient is asked to push the leg back down to the table using isometric contractions. During postisometric relaxation, the osteopathic physician moves the leg further into extension. This procedure is repeated until improved hip extension is achieved. The same treatment can be performed with (B) the patient in a supine position. In such a case, the osteopathic physician places the patient's leg off the end of the table and maintains an isometric balance, while the patient pushes the leg upward.

piriformis muscle.¹

The piriformis muscle is 1 of the primary external rotators of the hip when the leg is extended. When the leg is flexed, the piriformis muscle becomes responsible for hip abduction.¹¹ The piriformis has attachment points at the anterior surface of the sacrum and the greater trochanter of the femur.⁵ The sciatic nerve typically exits the pelvis just inferior to the piriformis muscle. In approximately 15% of the general population, the common fibular branch of the sciatic nerve passes through the belly of the piriformis muscle.¹² Rarely (in about 0.5% of the population), the common fibular nerve exits the pelvis superior to the piriformis muscle.¹²

The close approximation of the sciatic nerve is the reason that increased tone of the piriformis muscle could cause irritation to the sciatic nerve. Irritation to the sciatic nerve in patients with left psoas syndrome often causes pain that radiates down the back of the right leg and stops at the knee.^{1,2} Stretching the piriformis by hip and knee flexion, hip adduction, and internal rotation may help alleviate symptoms. Nonsteroidal anti-inflammatory drugs, moist heat, and injections of local anesthetic, corticosteroids, or botulinum toxin have also demonstrated benefits in treatment.¹¹

Our patient did not follow the typical compensation pattern of sacral dysfunction. Typically, the sacrum rotates on a left oblique axis in patients with left psoas syndrome. Our patient, however, had a left rotation on a right axis. This condition could have been attributed to the long duration of the patient's symptoms, to previous chiropractic manipulation, or to possible examiner error.

To relax and lengthen the psoas muscle, OMT should be used as a treatment modality. In a study in which

OMT—in the form of counterstrain; high-velocity, low-amplitude; muscle energy; and myofascial release—was used to treat patients with acute low back pain, the researchers used functional magnetic resonance imaging to evaluate low back muscles and compare transverse relaxation time before and after OMT.¹³ They found a statistically significant reduction in the transverse relaxation time asymmetry of the psoas muscle immediately after OMT ($P=.05$). This result means that the asymmetry in muscle activity was decreased with OMT.¹³

Muscle energy can be particularly useful to help the psoas muscle relax. This treatment can be performed with the patient lying prone and the osteopathic physician standing at the side of the table (*Figure 5A*). The osteopathic physician then lifts the leg on the involved side (the left leg in our patient's case), extending the hip. The osteopathic physician's other hand is used to apply pressure to the pelvis from the opposite (ie, posterior) side, to block linkage during the treatment. The patient is asked to push the leg back down to the table using isometric contractions. A contraction is held for 3 to 5 seconds, and then the patient is asked to relax. During the period of postisometric relaxation, the osteopathic physician moves the leg further into extension. This procedure is repeated until improved hip extension is achieved.⁶

The same treatment may be performed with the patient in a supine position (*Figure 5B*). The osteopathic physician, in that case, places the patient's leg off the end of the table and maintains an isometric balance, while the patient pushes the leg up toward the ceiling. This technique is useful in such conditions as pregnancy, when a prone position is not desirable.⁶

An inexpensive treatment modality that may be of

benefit involves stretches performed by the patient at home. A modified version of the lunge stretch that was assigned to our patient as a home stretch is shown in *Figure 2*. Even a simple position, such as the patient resting supine on the floor with his or her hips flexed to 90° and his or her feet and knees on a chair (*Figure 6*),

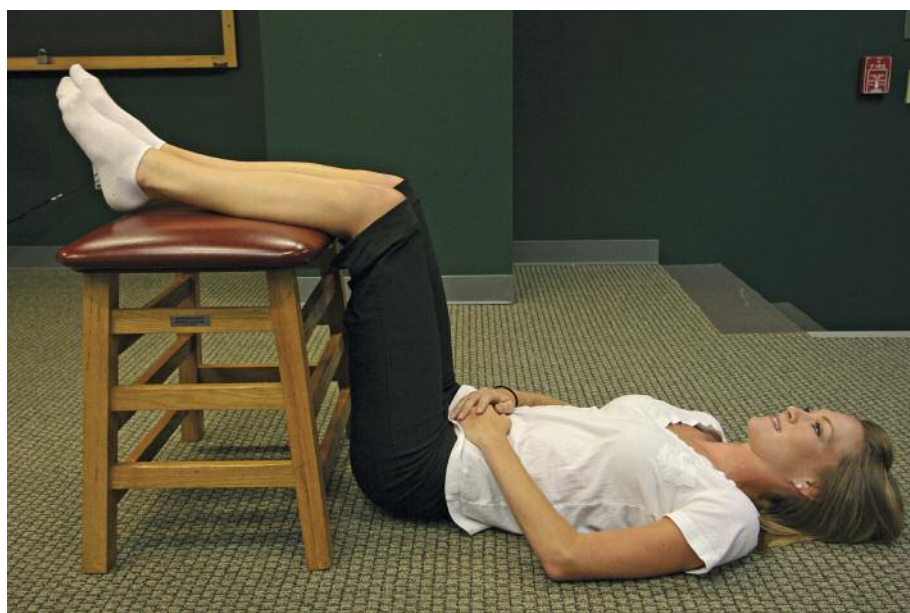


Figure 6. Resting supine on the floor with hips flexed to 90° and feet and knees on a chair has been shown to reduce pain in patients with psoas syndrome. Such a position shortens the psoas muscle by bringing the origin and insertion of the muscle closer together.

CASE REPORT

has been shown to reduce pain.¹⁰ Such a position shortens the psoas muscle by bringing the origin and insertion of the muscle closer together.¹⁰

Conclusion

Psoas syndrome is a complex musculoskeletal disorder in which the diagnosis may easily be missed. However, by keeping this diagnosis in mind when a patient presents with low back pain, the osteopathic physician can properly make the diagnosis and treat the patient with OMT, leading to a rapid improvement in symptoms in a relatively short time. A combination of OMT with home stretches constitutes an effective approach to the treatment of a patient with psoas syndrome.

References

1. Diagnosis and manipulative treatment: thoracic region. In: Kuchera WA, Kuchera ML. *Osteopathic Principles in Practice*. 2nd ed. Columbus, OH: Greyden Press; 1994:480-488.
2. Kuchera WA. Lumbar region. In: Ward RC, ed. *Foundations for Osteopathic Medicine*. 2nd ed. Philadelphia, PA: Lippincott Williams & Wilkins; 2003:747-748.
3. Sutherland WG. *Teachings in the Science of Osteopathy*. Portland, OR: Rudra Press; 1990:279-281.
4. Chapter 11. Posterior abdominal wall. In: Morton DA, Foreman KB, Albertine KH. *The Big Picture: Gross Anatomy*. New York, NY: McGraw-Hill Medical; 2011.
5. High-velocity, low-amplitude techniques. In: Nicholas AS, Nicholas EA. *Atlas of Osteopathic Techniques*. 2nd ed. Philadelphia, PA: Lippincott Williams & Wilkins; 2011:294,298.
6. DiGiovanna EL, Schiowitz S, Dowling DJ. *An Osteopathic Approach to Diagnosis and Treatment*. 3rd ed. Philadelphia, PA: Lippincott Williams & Wilkins; 2004.
7. Rancont CM. Chronic psoas syndrome caused by the inappropriate use of a heel lift. *J Am Osteopath Assoc*. 2007;107(9):415-418.
8. Low back pain. In: Pecina MM, Bojanic I. *Overuse Injuries of the Musculoskeletal System*. 2nd ed. Boca Raton, FL: Informa Healthcare; 2004:171-172.
9. Deslandes M, Guillin R, Cardinal E, Hobden R, Bureau NJ. The snapping iliopsoas tendon: new mechanism using dynamic sonography. *AJR Am J Roentgenol*. 2008;190(3):576-581.
10. Nelson KE, Schilling Mnabhi AK. The patient with back pain: short leg syndrome and postural balance. In: Nelson KE, Glonek T, eds. *Somatic Dysfunction in Osteopathic Family Medicine*. Baltimore, MD: Lippincott Williams & Wilkins; 2006:426-427.
11. Kirshner JS, Foye PM, Cole JL. Piriformis syndrome, diagnosis and treatment. *Muscle Nerve*. 2009;40(1):10-18.
12. Neurovascular systems: topographical anatomy. In: Schuenke M, Schulte E, Schumacher U. *Thieme Atlas of Anatomy: General Anatomy and Musculoskeletal System*. New York, NY: Georg Thieme Verlag; 2005:493.
13. Clark BC, Walkowski S, Conatser RR, Eland DC, Howell JN. Muscle functional magnetic resonance imaging and acute low back pain: a pilot study to characterize lumbar muscle activity asymmetries and examine the effects of osteopathic manipulative treatment. *Osteopath Med Prim Care*. 2009;3:7.

Download JAOA PowerPoint Slides

Figures published in *JAOA—The Journal of the American Osteopathic Association* are now available as Microsoft PowerPoint slides on the JAOA's Web site. To take advantage of this new resource, JAOA readers should simply click on the link "Download as PowerPoint slide" when viewing the figure in the full text article on JAOA.org. Readers can also download all figures in an article by selecting the option "PPT Slides of All Figures" in the middle column of the Web page.